

.....

Current and Emerging Views and Treatments of Systemic Immunoglobulin Light-Chain (AL) Amyloidosis

Raymond L. Comenzo

Cytotherapy Laboratory, Memorial Sloan-Kettering Cancer Center,
New York, N.Y., USA

Abstract

Amyloidosis is a disease in which abnormal proteins form toxic intermediates and fibrillar tissue-deposits that compromise key viscera and lead to early death. In order to treat amyloidosis, the type of abnormal protein must be identified. The most common type is monoclonal immunoglobulin light chain or AL amyloidosis. One-third to one-half of patients with systemic AL amyloidosis has renal involvement in the form of glomerular, vascular and interstitial deposits of amyloid causing progressive proteinuria. Less than 5% of AL patients present with renal failure requiring dialysis; patients with renal involvement usually present with fatigue, peripheral edema, proteinuria and hypoalbuminemia. The aim of therapy in systemic AL amyloidosis is to reduce the amyloid-forming monoclonal light chains, measured with the serum free light chain assay, by suppressing the underlying plasma cell dyscrasia, while using supportive measures to sustain organ function. Amyloid deposits can be resorbed and organ function restored if the amyloid-forming precursor light chain is eliminated. The most effective treatment for systemic AL is risk-adapted melphalan with peripheral blood stem cell transplant; oral melphalan and dexamethasone is the most effective therapy for patients who are not stem cell transplant candidates although it carries a risk of myelodysplasia and leukemia. Novel therapies currently under study include thalidomide, bortezomib and lenalidomide. With therapy, a majority of patients can achieve long-term durable remissions with stabilization or recovery of organ function. The use of novel antibody-based approaches for imaging amyloid and possibly for accelerating removal of deposits is under active investigation.

Copyright © 2007 S. Karger AG, Basel

Amyloid is an abnormal insoluble extracellular fibrillar protein that resists protease digestion and has the pathognomonic characteristic of red-to-green

dichroism when stained with Congo red and viewed microscopically under polarized light [1–3]. Over 20 different proteins have the propensity to form amyloid fibrils and cause systemic amyloid disease; these ‘fibril–precursor’ proteins determine the type of amyloid that a patient has. All amyloid, no matter the type, has as its distinctive component linear non-branching haphazardly arranged protein fibrils about 7–10 nm in diameter [4]. The fibrils are the final products of a pathway that remains rudimentarily understood.

With few exceptions, the fibril–precursor proteins are made by normal cells. In some cases, such as β_2 microglobulin amyloid associated with hemodialysis or wild-type transthyretin amyloid associated with senile systemic amyloidosis, the fibril–precursor protein paradoxically is a normal protein. In the most common type of systemic amyloidosis, immunoglobulin (Ig) light-chain or AL amyloidosis, the fibril–precursor protein is the product of a clonal B-cell disorder, usually of the terminally differentiated clonal plasma cells of a monoclonal gammopathy. Therefore, in systemic AL amyloidosis, both the fibril–precursor protein (an aberrant Ig light chain) and the cells producing it (clonal plasma cells) are abnormal.

Systemic AL amyloidosis is a rare disorder with an incidence estimated to be 8 per million person-years. The median age at diagnosis is about 60 and the median survival of patients seen within 1 month of diagnosis is about a year without treatment. Prior to the use of autologous stem cell transplant (SCT), <5% of patients lived 10 years or more from diagnosis [5, 6]. Renal involvement is common in AL amyloidosis and contributes significantly to the morbidity of the disease. For example, of 445 patients with systemic AL amyloidosis reported by the Italian Amyloidosis Study Group, 53% had renal protein losses exceeding 3 g/day and 19% had serum creatinine levels ≥ 2 mg/dl [7]. Patients with renal involvement presented most frequently with fatigue and edema.

In this chapter, we discuss new views of AL amyloidosis with emphasis on various aspects of the Ig light chain fibril–precursor protein as toxic intermediate, renal-tropic protein and target of therapy, and focus on clinical aspects of renal involvement and on current and emerging ways to treat AL disease.

Amyloid Fibrils and Precursor Protein Toxic Intermediates

The steps of fibril formation have been inferred from the study of protein fragments derived from deposits and from in vitro studies [8]. The current view is that fibril–precursor monomers, usually comprised of N-terminal fragments of the whole precursor protein, bind each other hydrostatically into stable intermolecular stacks of β -sheets perpendicular to the fibril axis, forming a filament [9–11]. Four to six filaments then twist about each other like the strands of a rope to form the fibril. No matter the type, all amyloid fibrils share this structure,

a curious happenstance given the diverse native conformations of fibril-precursor proteins with respect to the presence or absence of β -strand domains or β -sheets. Minor components of the amyloid deposits include heparan sulphate proteoglycans, serum amyloid P (SAP) protein and apolipoprotein E. The roles of these minor components have not been fully elucidated but experimental evidence, including knock-out studies, indicate that SAP likely protects fibrils by impairing proteolysis [12]. Proteoglycans and apolipoprotein E polymorphic variants may provide important surface features or niches that enable fibril propagation [13].

How amyloid fibrils cause organ dysfunction is not well defined. Suggested mechanisms include mechanical disruption, oxidative stress and formation of aberrant ion channels [14–16]. How fibrils are metabolized and organs improve is no less mysterious. The liver, e.g., can tolerate a large burden of AL amyloid without failing and, once treatment eliminates the supply of fibril-precursor Ig light-chains, the liver can respond with restoration of normal synthetic function and dramatic regression to normal size. These changes can happen over a period of 6–12 month. This is attributed to the regenerative capacity of the liver but begs the question as to how the fibrils are removed.

In contrast, 1 year after elimination of the clonal Ig light-chains, only 20% of patients with cardiac amyloidosis show measurable reduction in left ventricular wall thickness [17]. Indeed, a patient's clinical status with AL is not simply determined by the amyloid burden; patients with peripheral nervous system or cardiac involvement can have minimal tissue burdens of amyloid but advanced symptomatology and organ-system failure. The use of I^{123} -labeled SAP to image amyloid tissue burden with total body scintiscans, although limited in availability, has revealed how labile amyloid deposits can be; however, a significant fraction of patients who experience elimination of the clonal Ig light-chains do not demonstrate reduction in amyloid burden despite clinical improvement and abatement of symptoms [18].

Response of the plasma cell disease after treatment in large measure determines amyloid organ response. Patients with renal amyloid and normal renal function prior to SCT who achieve a complete hematologic response (CR, immunofixation negative with normal serum free light chains [FLC]) post-SCT are after 1 or 2 years highly likely to experience a significant reduction in proteinuria and an increase in serum albumin (with no loss of renal function) (fig. 1) [19]. Similar patients who fail to achieve a CR post-SCT are likely to have stable proteinuria for a period of time but can progress to end-stage renal disease and dialysis-dependence in the 5 years post-SCT. How and why improvement in proteinuria occurs over 1–2 years in complete responders remains obscure; repeat biopsies of surrogate sites such as abdominal fat continue to show amyloid deposits. It is unlikely that glomerular amyloid deposits

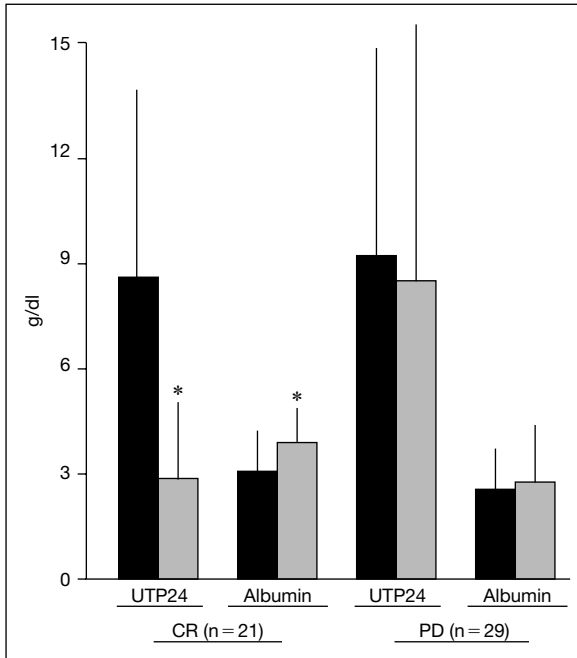


Fig. 1. This figure depicts the outcomes in 50 consecutive AL patients with dominant renal involvement (spilling > 1 g/day) who underwent autologous SCT as described in reference [19]. Twenty-one patients experienced a CR while 29 had persistent clonal disease (PD) at 1 year after SCT. The drops in UTP24 and increases in serum albumin were significant for patients with CR by two-tailed paired t-test (means \pm standard deviations shown). There was no change in either measure for patients with PD (* $p < 0.05$). UTP24 = 24-hour total urinary protein.

are resorbed and therefore it is more likely that effective treatment controls the toxic effects of Ig light chains.

Such observations have led to the view that amyloid fibrils per se may not be the sole pathologic basis of amyloid disease [20]. Experiments in vitro with several fibril-precursor proteins have shown that intermediate forms or oligomeric aggregates may be more toxic to cells than fibrils, hence the term 'toxic intermediates.' Indeed fibrils may represent a less toxic form of the fibril-precursor protein and may provide relative protection [21]. The relationship between fibrils and intermediates in the various types of amyloidosis remains undefined and the role of intermediates in disease is unclear. However, if experimental systems can be developed to elucidate the mechanisms of toxicity, an opportunity to pursue novel protective therapies will likely be created.

Immunoglobulin Light Chains and the Kidneys

Immunoglobulin light chains are produced in slight excess by normal plasma cells and in significant excess at times by aberrant clonal plasma cells. In the absence of Ig light chain variable regions, Ig heavy chain variable regions tend to aggregate because they possess a large hydrophobic surface area that remains exposed without the cover of light chain partners. Hence, unassociated Ig heavy chains are usually retained intracellularly and degraded while unassociated Ig light chains usually fold more adeptly and attain secretory competence.

Ig light chains circulate in normal individuals and can be measured with the recently available serum FLC assay [22]. Over 95% of patients with systemic AL amyloidosis have abnormal levels of serum FLC, and the abnormally elevated FLC usually is the fibril-precursor protein. The pathologic Ig light chain level in AL is probably proportional to the size of the abnormal plasma cell clone; however, there is likely inter-patient variability in Ig light chain production per clonal plasma cell that has not been well-described or explained. In addition, the AL disease process has a significant though difficult to measure claim on the elimination kinetics of serum FLC. In normal individuals without renal insufficiency, serum free κ light chain levels are lower than λ . In normal bone marrow and the normal expressed repertoire of immunoglobulins, the κ -to- λ ratio is 3:2. The κ light chain is usually a monomer of ~ 25 kDa while the λ light chain is usually a dimer of ~ 50 kDa and is cleared more slowly by the kidneys [23]. The slower clearance of λ light chains likely explains the higher free λ levels observed in normals, but is not thought to play a major role in systemic AL amyloidosis.

The serum FLC assay has significantly changed the way that patients with AL amyloidosis are diagnosed and monitored during therapy. The FLC assay is quantitative, unlike immunofixation, and appears more sensitive to the presence of clonal disease than immunofixation in some cases [18, 24]. A series of FLC values in newly diagnosed patients with amyloidosis is depicted in figure 2a. The FLC can help to distinguish hereditary from AL amyloid and localized from systemic AL, although FLC values are minimally elevated in about one-quarter of patients who have localized AL disease. In figure 2b, the proteinuria and serum FLC levels of an AL patient during treatment are shown, illustrating how renal response follows FLC response.

It is important to note that rare patients with amyloid can have two possible sources of fibril-precursor proteins, a monoclonal gammopathy, including elevated serum FLC, and an hereditary amyloid protein [25, 26]. At minimum, African-Americans with amyloid and patients presenting with peripheral neuropathy should be checked for the presence of both possible sources and referred to specialized centers for tissue-typing studies if both precursor proteins are identified.

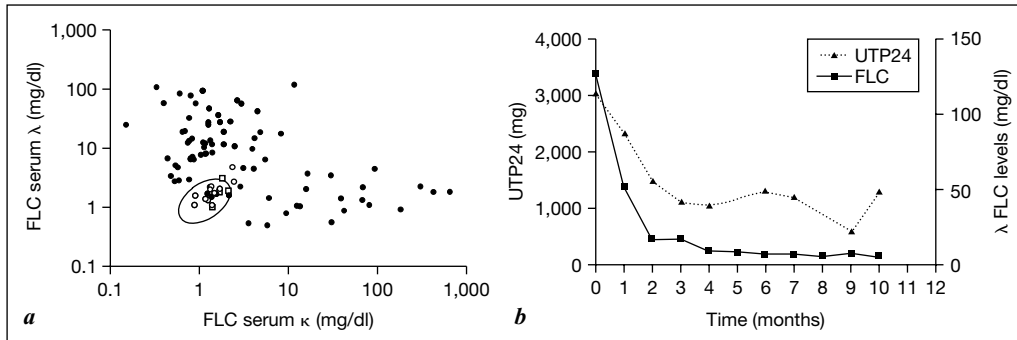


Fig. 2. *a* shows the serum FLC levels with axes in \log_{10} format for 110 newly diagnosed patients with amyloidosis seen at Memorial Sloan-Kettering from 2002 to 2004. The solid circles ($n = 92$) are systemic Ig light chain (AL) patients, open circles are localized AL patients ($n = 11$) and open squares are hereditary (ATTR, $n = 6$) patients. The oval near the origin is the normal range for the ratio of κ -to- λ . *b* shows the UTP24 and λ FLC levels for a 73-year-old man with renal, cardiac and autonomic nervous system involvement who received monthly oral melphalan and dexamethasone with a response. Over the 10 months of therapy the brain natriuretic peptide level also decreased from 3,280 to 1,670 pg/ml. The graph illustrates how renal response follows FLC response. UTP24 = 24-Hour total urinary protein.

Because of their small size, Ig light chains are filtered by the glomeruli, and resorbed and metabolized in the proximal tubules by a receptor-mediated process. In states of light-chain overproduction, light chains appear in the urine because tubular reabsorption is overwhelmed. In light-chain myeloma, proteinuria is selective and predominantly Ig light chains. In AL amyloidosis, proteinuria is non-selective, and the dominant protein, albumin, is bound to fatty acids. Progression of proteinuria in AL portends end-stage renal disease and may both indicate and accelerate worsening renal function. Ig light chains can aggregate in tubules causing cast nephropathy or can damage glomeruli and tubules by depositing amorphously or as fibrils, causing glomerulosclerosis and tubulointerstitial scarring. In AL amyloidosis, the pattern of fibril deposition is usually glomerular, interstitial and vascular. Tubular deposition patterns, though rare, do occur and are usually associated with rapidly progressive renal insufficiency with minimal proteinuria. Why some light chains cause AL renal involvement and others do not is not known. Indeed, the organ tropism of AL amyloidosis remains poorly understood.

We hypothesized that immunoglobulin germline gene use played a role in organ tropism and several years ago tested the hypothesis that the light chain variable region (Ig V_L) germline genes used by AL clones influenced organ

tropism. The clonal Ig V_L genes of patients with B cell disorders can be amplified, sequenced, assigned germline gene donors and assessed for homology to the germline sequences. This type of analysis allows one to show whether or not the germline genes used in a particular B cell disorder vary preferentially from the normal repertoire.

To test our hypothesis regarding germline gene use and organ tropism, we amplified, cloned and sequenced the clonal Ig light chain genes from 60 AL patients [27]. To assess the renal effects of some light chains, we used an in vitro renal mesangial cell model of amyloid formation [28, 29]. In the V λ cases, there was preferential germline gene utilization. The 1c gene was used in 8 of 15 V λ I cases, 2a2 in 6 of 7 V λ II cases, 3r in 7 of 8 V λ III cases, and the 6a gene in all 18 V λ VI cases. In the normal expressed repertoire, 7–8% of λ light chains are derived from 1c, 20–35% from 2a2, 7–8% from 3r, and <5% from 6a [30]. Light chains of the rare V λ VI subtype have been found frequently in AL [31]. In the V κ cases, there was also preferential utilization. The relatively rare LFVK431 germline gene was used in 4 cases and the more common O18–O8 gene in 7. All of the V κ genes used by the clones in this series were members of the V κ I subtype. In normal usage, genes of the V κ III subtype dominate [32].

With respect to organ tropism, we learned that the 1c, 2a2 and 3r germline genes were associated with dominant cardiac and multisystem disease (10 of 21 patients), while the 6a gene was associated with dominant renal disease (16 of 18 patients). Indeed, the association between the 6a donor and dominant renal involvement was striking and a comparison of the frequency of dominant renal involvement in 6a patients versus all others was highly significant ($p < 0.01$, $\chi^2 = 12.61$, d.f. = 1, relative risk = 2.5, 95% CI = 1.56–4.02). Furthermore, in the in vitro model, unlike all other light chains, 6a light chains formed amyloid rapidly both with and without amyloid-enhancing factor. These observations regarding the renal tropism of 6a light chains, though striking, remain undeveloped. The mechanisms and pathways involved in the renal-tropic toxicity of 6a light chains are not yet known.

Renal Involvement in AL Disease

In general, one-third to one-half of AL patients will have renal involvement at diagnosis, often presenting with nephrotic syndrome without hypertension and findings of peripheral edema, frothy urine, low serum albumin and elevated cholesterol. Hypotension may also be a presenting sign and may be due to hypoalbuminemia and plasma volume depletion, reduced cardiac output due to severe diastolic dysfunction or autonomic neuropathy. Many patients with renal involvement are diagnosed after proteinuria is serendipitously revealed;

a minority will have daily proteinuria of 10 g or more. AL amyloidosis infrequently presents as renal failure.

Typically the finding of excess proteinuria leads to renal biopsy, securing the diagnosis; amyloidosis is found in about 3% of renal biopsies. Anasarca and massive proteinuria with hypoalbuminemia but normal serum creatinine and blood urea nitrogen may occur, although evidence of mild renal dysfunction is most commonly found. In patients with malignant nephrosis, the use of diuretics and albumin may be poorly tolerated and bilateral embolization of the renal arteries may be considered; such cases are rare. The presence of pleural and pericardial effusions can give the picture of heart failure. Patients are salt-avid but may be volume-depleted, causing nausea and vomiting and complicating attempts at diuresis. Volume-depletion can also cause orthostasis mimicking autonomic neuropathy.

In AL, the urine sediment is usually unremarkable, containing variable numbers of red blood cells and fatty droplets. Patients have kidneys that by ultrasound are normal in size but usually demonstrate echo findings consistent with medical renal disease. Rarely, patients may have both amyloid and light-chain nephropathy or light-chain deposition disease on renal biopsy. Continuous proteinuria leads to worsening renal function and eventually to end-stage renal disease requiring dialysis. Historical patient series indicate that the median time to dialysis-dependence for AL patients presenting with nephrotic-range proteinuria is about 15 months, and the major determinant of survival is the presence or absence of amyloid involvement of the heart [33, 34].

Current Treatments

For patients with systemic AL amyloidosis, the FLC assay provides a direct measure of the fibril-precursor protein, whether the aberrant B cell factory for FLC production is a plasma cell dyscrasia or a non-Hodgkin lymphoma [35]. A major problem in treating AL patients has been gauging response and titrating therapy, since the response of amyloid organ disease lags behind the reduction in the fibril-precursor protein. This is a critical clinical point. Therefore, integration of the FLC into clinical practice allows the titration of therapy to determine when the optimal response of the clonal disease has been attained. This is usually before an organ response and clinical improvement may be evident. Stable declines in the FLC of >50% from baseline values have been shown to be associated with prolonged survival in systemic AL patients after treatment [36].

Oral melphalan and prednisone were studied in phase III trials and increased overall survival from 12 to 18 months [37, 38]. Responses (>50% reductions) occurred in 25% of patients with a median time to response of

12 months; renal disease improved in 17%. For patients who survived more than 3.5 years after receiving oral melphalan, there was a high risk of myelodysplasia often leading to secondary leukemia [39]. The Southwestern Oncology Group (SWOG) conducted a multi-center phase II trial testing pulse dexamethasone, followed by maintenance therapy with dexamethasone and α interferon, in patients with AL [40]. Responses were seen in 53% of evaluable patients with complete responses (CR) in 24%. Organ responses occurred in 45% of patients. Median survival of the entire cohort was 31 months, with estimated 2-year overall and event-free survivals of 60 and 52%.

Recently, the Italian Amyloidosis Center completed a phase II trial combining oral melphalan with dexamethasone in patients with AL not eligible for SCT [41]. This combination led to a response in 67% of patients with a 33% CR rate and a median survival that had not been reached with nearly 4 years of follow-up (G. Merlini; personal communication). In 48% of the responsive patients organ responses were observed. FLC measurements were not available. There were 2 treatment-related deaths in the first 100 days of therapy and 2 patients also subsequently developed myelodysplasia.

Oral melphalan and dexamethasone are clearly an active regimen based on these data, are easily administered and can be considered equivalent in some respects to melphalan-based SCT except for the risk of myelodysplasia and secondary leukemia. Time to response is an important variable in treating systemic AL amyloidosis. The combination of melphalan and dexamethasone appears significantly more active than melphalan and prednisone with a time to response of 3 months.

The effectiveness of high-dose melphalan with autologous SCT in reversing the clinical manifestations of AL in most surviving patients has been documented at numerous centers [42–44]. As the production of amyloid stops, the quality of life of AL patients improves [45]. Objective criteria for assessing organ responses have recently been defined [46]. In the largest series of patients reported, the median overall survival post-SCT was 4.6 years with 47% survival at 5 years [47]. For patients without cardiac involvement at SCT, the median survival was 6.4 years with 60% 5-year survival, while for those with cardiac involvement at SCT the median survival was 1.6 years with 29% 5-year survival. Treatment-related mortality was 19%, including toxicities of stem cell mobilization. Forty-four percent of evaluable patients achieved organ responses at 1-year post-SCT. Complete hematologic responses occurred in 40% of patients surviving at 1 year post-SCT and were associated with an 82% 5-year survival compared to 55% for those not achieving CR. Controversial aspects of this single-center experience include the high treatment-related mortality and the fact that many patients at the time of SCT were more than 1 year from diagnosis and had prior treatments.

Renal Transplantation

The use of solid organ transplantation (liver, heart and kidney) in patients with AL amyloidosis is frequently deemed inappropriate because of the likely accumulation of amyloid in the grafted organ. Liver transplant, in contrast, is a therapy of choice for hereditary amyloidosis and has even led to the use of ‘domino’ grafts in which the otherwise normal mutant-TTR producing liver is used as an allograft [48]. This situation is slowly changing. In the past decade a number of AL patients have successfully undergone cardiac allograft and then SCT; the feasibility of this approach is established and a phase II trial needs to be performed to demonstrate safety and efficacy in a systematic fashion [49]. Renal transplantation has also been shown to be effective, and renal allografts survive for lengthy periods in many recipients especially after SCT [50]. Renal failure requiring dialysis develops in about a third of patients after 2 years despite standard oral therapy but only in about 10% of patients after dose-intensive therapy with stem cell support.

Emerging Therapies

New agents with novel mechanisms of action are being evaluated for the treatment of multiple myeloma and other plasma cell dyscrasias. These include the immunomodulators thalidomide and lenalidomide as well the proteasome-inhibitor bortezomib. These agents and novel monoclonal antibody approaches to amyloidosis are entering clinical trials. Phase I/II clinical trials testing the single-agent activity of lenalidomide and bortezomib are on-going at this time; preliminary data indicate that both have activity.

Two small phase I/II clinical trials have been conducted testing the toxicity and efficacy of thalidomide in AL amyloidosis. Both demonstrated that thalidomide had significant toxicity and minimal activity [51, 52]. Two other phase II trials, however, tested the combination of thalidomide and dexamethasone as therapy for AL. In one, the combination was used as salvage therapy, while in the other the combination was used as adjuvant therapy after melphalan-based SCT. The results of these studies indicate that thalidomide and dexamethasone should likely be regarded as first-line salvage therapy at this time pending the results of the lenalidomide and bortezomib trials.

In the Italian Amyloidosis Center’s phase II trial of thalidomide and dexamethasone combined as salvage therapy [53], thalidomide was dosed at 100 mg/day with increments up to 400 mg and dexamethasone at 20 mg/day on days 1–4 every 3 weeks. Thirty-one patients with AL refractory to or in relapse after first-line therapy were enrolled. Eleven patients (35%) tolerated 400 mg/day of thalidomide for

a median of 6 months; 14 could take no more than 100 or 200 mg/day for a median of 3 months. Fifteen (48%) achieved a hematologic response with 19% complete remissions and 26% organ responses; the response rate was higher in those taking higher doses of thalidomide. Overall median time to response was 3.6 months. There were no treatment-related deaths but two-thirds experienced severe toxicity. Fluid retention and symptomatic bradycardia without QT prolongation were common adverse reactions while neuropathic and thromboembolic complications were rare.

At Memorial Sloan-Kettering Cancer Center, we recently conducted a phase II clinical trial for newly diagnosed AL patients eligible for autologous SCT, combining melphalan-based SCT with the use of thalidomide and dexamethasone. To be eligible for autologous SCT, patients had to have only 1 or 2 major organs significantly involved and could have cardiac involvement that was not advanced. After SCT, patients with persistent plasma cell disease received thalidomide and dexamethasone as adjuvant therapy [54]. Our goals were low treatment-related mortality and optimal hematologic and organ response rates. To be eligible, patients had to be untreated and diagnosed within 12 months of enrollment.

Patients received autologous SCT with melphalan dosed at 200, 140 or 100 mg/M² based on age, renal function, and cardiac involvement. Those not achieving a CR at 3 months post-SCT were treated with 9 months of thalidomide (50–200 mg nightly) and dexamethasone (20 mg/M², 1–3 pulses monthly), or with only dexamethasone if they had prior deep venous thrombosis or neuropathy. Aspirin was used for prophylaxis against thromboembolic complications.

Forty-five untreated patients (23 men) enrolled, a median of 57 years old (range = 34–73) and 2 months from diagnosis. Over two-thirds had renal involvement (31/45) with median proteinuria 5.95 g/day (range = 0.51–22.1 g/day) compared to 0.184 g/day (range = 0–0.475 g/day) for those without renal involvement. Two-thirds of those with renal involvement (21/31) had been diagnosed with renal biopsy, the remainder with surrogate site or other involved-organ biopsies. Two patients presented at diagnosis with creatinine clearance <20 ml/min, one requiring hemodialysis and the other soon to require it, making the incidence of systemic AL amyloidosis presenting as renal failure in this cohort 4.4% (2/45).

Dominant organ involvement in these 45 patients was renal in 58% (n = 26), cardiac in 24% (n = 11), and liver/GI or peripheral nervous system in 18% (n = 8). A third (n = 15) had 2 organ systems involved. At baseline 53% had elevated serum brain natriuretic peptide levels, suggestive of cardiac involvement. Dose-assignments were 200 (n = 15), 140 (n = 24) and 100 mg/m² (n = 6) of melphalan. Treatment-related mortality was 4.4% (2/45). At 3 months post-SCT, persistent clonal disease was found in 34 patients; 1 refused and 2 were too ill for

adjuvant therapy. Twenty-two patients received thalidomide and dexamethasone, and 9 received dexamethasone alone. With adjuvant therapy 48% had an improved response at 12 months including 6 who achieved CR. There were no treatment-related deaths in the adjuvant phase and toxicities were manageable. The hematologic response rate at 12 months was 77% (38% CR) with no significant difference based on the dose of melphalan. Fifty-two percent had organ responses at 12 months, while 29% had stable and 19% worsened organ function. With a median follow-up of 20 months, overall survival is 76% and median survival is not yet reached.

In the 31 patients with renal involvement the hematologic response rate at 1 year was 77% with 45% complete responders; 71% (22/31) received adjuvant therapy post-SCT. At 2 years post-SCT, 45% of the patients (14/31) had improvement in renal disease defined as a >50% reduction in proteinuria with no loss of renal function, while 29% (9/31) had stable renal disease. In the 14 patients with renal responses, mean (\pm standard deviation) 24-h proteinuria declined from baseline $7,270 \pm 6,582$ to $1,993 \pm 1,759$ mg ($p < 0.01$ by paired t-test). All but one of those with a renal response had a hematologic response as well. Two patients required hemodialysis shortly after diagnosis (serum creatinine >7.0 mg/dl in both cases) and beginning treatment, as noted earlier; one successfully received a renal allograft from a spouse donor 1 year post-SCT. An additional 2 patients experienced toxicities of SCT (veno-occlusive disease, sepsis) that led to dialysis-dependence. Overall survival for these 31 patients at 2 years post-SCT is 87% (27/31); three patients died of progressive amyloidosis and one died of an unrelated illness.

These results promise improved outcomes as novel agents are incorporated into the platform provided by melphalan-based therapy; indeed, lenalidomide or bortezomib combined with dexamethasone may challenge melphalan-based approaches as initial therapy for AL. Systematic multi-center clinical trials will be needed to define the optimal roles of emerging treatments for AL.

Monoclonal antibody therapy has had significant impact on the treatment of non-Hodgkin lymphoma, and breast and lung cancers. The development of amyloid-reactive antibodies was based on the premise that an immune reaction to amyloid deposits might help to stimulate fibril disassembly [55, 56]. Amyloid tumors formed in the skin of healthy mice resolved within several weeks after the generation of anti-amyloid antibodies that recognized antigenic determinants on AL amyloid fibrils. 'Amyloidolysis' occurred in treated but not untreated animals. The antibody localized within the amyloid tumors and caused rapid resorption of this material by neutrophils. The manufacture of a chimeric antibody is currently complete and clinical trials are beginning in the near future. One of the first applications will be imaging amyloid deposits by PET/CT with I^{124} -labeled antibody, a collaborative clinical trial undertaken by

investigators at the University of Tennessee and Memorial Sloan-Kettering Cancer Center.

Active research is underway at several centers to find unique plasma cell antigens that can provide targets on the surface of the aberrant clonal plasma cells that cause AL and other disorders such as multiple myeloma. The availability of effective cytolytic antibody therapy would likely result in a significant improvement in survival for AL patients, possibly even for those with multi-organ failure whose clinical status would preclude current therapies because of toxicity.

Conclusions

Our views of systemic AL amyloidosis and our approaches to its treatment are rapidly evolving. The serum FLC assay has made diagnosis and treatment more focused since it provides a measure of the fibril-precursor protein. The growth of autologous SCT and the use of novel agents to treat AL has created further incentives for physicians to diagnose the disease earlier in its course. A majority of patients diagnosed today can be helped significantly with approaches designed to eliminate the supply of fibril-precursor Ig light chains. Ideally, patients with AL should be treated on clinical trials whenever possible. Hopefully, in the near future novel imaging and monoclonal antibody approaches will be available for evaluation, and in the not-too-distant future rationally designed cytoprotective agents will also be in clinical trials as well.

References

- 1 Merlini G, Bellotti V: Molecular mechanisms of amyloidosis. *N Engl J Med* 2003;349:583–596.
- 2 Kelly JW: Towards an understanding of amyloidosis. *Nat Struct Biol* 2002;9:323–325.
- 3 Pepys MB: Amyloidosis. *Ann Rev Med* 2006;57:223–241.
- 4 Falk RH, Comenzo RL, Skinner M: The systemic amyloidoses. *N Engl J Med* 1997;337:898–909.
- 5 Kyle RA, Linos A, Beard CM, et al: Incidence and natural history of primary systemic amyloidosis in Olmstead County, Minnesota, 1950 through 1989. *Blood* 1992;79:1817–1822.
- 6 Kyle RA, Gertz MA, Greipp PR, et al: Long-term survival (10 years or more) in 30 patients with primary amyloidosis. *Blood* 1999;93:1062–1066.
- 7 Merlini G, Westermark P: The systemic amyloidoses: clearer understanding of the molecular mechanisms offers hope for more effective therapies. *J Intern Med* 2004;255:159–178.
- 8 Wetzel R: Domain stability in immunoglobulin light chain deposition disorders. *Adv Protein Chem* 1997;50:183–242.
- 9 Ferreira ST, De Felice FG: Protein dynamics, folding and misfolding: from basic chemistry to human conformational diseases. *FEBS Lett* 2001;498:129–134.
- 10 Stevens FJ, Myatt EA, Chang CH, et al: A molecular model for self-assembly of amyloid fibrils from immunoglobulin light chains. *Biochem* 1995;34:10697–10702.
- 11 Ionescu-Zanetti C, Khurana R, Gillespie JR, et al: Monitoring the assembly of Ig light-chain amyloid fibrils by atomic force microscopy. *Proc Natl Acad Sci USA* 1999;96:13175–13179.

- 12 Tennent GA, Lovat LB, Pepys MB: Serum amyloid P component prevents proteolysis of the amyloid fibrils of Alzheimer disease and systemic amyloidosis. *Proc Natl Acad Sci USA* 1995;92:4299–4303.
- 13 Stevens FJ, Kiselevsky R: Immunoglobulin light chains, glycosaminoglycans, and amyloid. *Cell Mol Life Sci* 2000;57:441–449.
- 14 Janson J, Ashley RH, Harrison D, McIntyre S, Butler PC: The mechanism of islet amyloid polypeptide toxicity is membrane disruption by intermediate-sized toxic amyloid particles. *Diabetes* 1999;48:491–498.
- 15 Schubert D, Behl C, Lesley R, et al: Amyloid peptides are toxic via a common oxidative mechanism. *Proc Natl Acad Sci USA* 1995;92:1989–1993.
- 16 Engstrom I, Ronquist G, Pettersson L, Waldenstrom A: Alzheimer amyloid beta-peptides exhibit ionophore-like properties in human erythrocytes. *Eur J Clin Invest* 1995;25:471–476.
- 17 Falk R: Diagnosis and management of the cardiac amyloidoses. *Circulation* 2005;112:2047–2060.
- 18 Lachmann HJ, Gallimore R, Gillmore JD, et al: Outcome in systemic AL amyloidosis in relation to changes in concentration of circulating free immunoglobulin light chains following chemotherapy. *Br J Haematol* 2003;122:78–84.
- 19 Dember LM, Sanchorawala V, Seldin DC, et al: Effect of dose-intensive intravenous melphalan and autologous blood stem-cell transplantation on AL amyloidosis-associated renal disease. *Ann Int Med* 2001;134:746–753.
- 20 Khurana R, Gillespie JR, Talapatra A, et al: Partially folded intermediates as critical precursors of light chain amyloid fibrils and amorphous aggregates. *Biochem* 2001;40:3525–3535.
- 21 Kaye R, Head E, Thompson JL, et al: Common structure of soluble amyloid oligomers implies common mechanism of pathogenesis. *Science* 2003;300:486–489.
- 22 Bradwell A, Carr-Smith HD, Mead GP, et al: Highly sensitive automated immunoassay for immunoglobulin free light chains in serum and urine. *Clin Chem* 2001;47:673–680.
- 23 Drayson M, Tang LX, Drew R, GP Mead, Carr-Smith H, Bradwell AR: Serum free light-chain measurements for identifying and monitoring patients with nonsecretory multiple myeloma. *Blood* 2001;97:2900–2902.
- 24 Comenzo RL, Zhou P, Reich L, et al: Prospective evaluation of the utility of the serum free light chain assay (FLC), clonal Ig VL gene identification and troponin I levels in a phase II trial of risk-adapted intravenous melphalan with adjuvant thalidomide and dexamethasone for newly diagnosed untreated patients with systemic AL amyloidosis; in Grateau G, Kyle RA, Skinner M (eds): *Amyloid and Amyloidosis*: CRC Press, 2005, pp 167–172.
- 25 Lachmann HL, Booth DR, Booth SE, et al: Misdiagnosis of hereditary amyloidosis as AL (primary) amyloidosis. *N Engl J Med* 2002;346:1786–1791.
- 26 Comenzo RL, Zhou P, Fleisher M, Clark B, Teruya-Feldstein J: Seeking confidence in the diagnosis of systemic AL (Ig light-chain) amyloidosis: patients can have both monoclonal gammopathies and hereditary amyloid proteins. *Blood* 2006;107:3489–3491.
- 27 Comenzo RL, Zhang Y, Martinez C, Osman K, Herrera GA: The tropism of organ involvement in primary systemic amyloidosis: contributions of Ig VL germ line gene use and clonal plasma cell burden. *Blood* 2001;98:714–720.
- 28 Isaac J, Kerby JD, Russell WJ, Dempsey SC, Sanders PW, Herrera GA: In vitro modulation of AL-amyloid formation by human mesangial cells exposed to amyloidogenic light chains. *Amyloid* 1998;5:238–246.
- 29 Herrera GA, Russell WJ, Isaac J, et al: Glomerulopathic light chain-mesangial cell interactions modulate in vitro extracellular matrix remodeling and reproduce mesangiopathic findings documented in vivo. *Ultrastruct Pathol* 1999;23:107–126.
- 30 Ignatovich O, Tomlinson IM, Jones PT, Winter G: The creation of diversity in the human immunoglobulin V-lambda repertoire. *J Mol Biol* 1997;267:69–77.
- 31 Solomon A, Frangione B, Franklin EC: Preferential association of the V I VI subgroup of human light chains with amyloidosis AL. *J Clin Invest* 1982;70:453–457.
- 32 Tomlinson IM, Cox JPL, Gherardi E, Lesk AM, Chothia C: The structural repertoire of the human V-kappa domain. *EMBO J* 1995;4:4628–4638.
- 33 Gertz MA, Kyle RA, O'Fallon WM: Dialysis support of patients with primary systemic amyloidosis: a study of 211 patients. *Arch Intern Med* 1992;152:2245–2250.

- 34 Montseny JJ, Kleinknecht D, Meyrier A, et al: Long-term outcome according to renal histologic
lesions in 118 patients with monoclonal gammopathies. *Nephrol Dial Transplant* 1998;13:1438–1445.
- 35 Cohen AD, Zhou P, Xiao Q, et al: Systemic AL amyloidosis due to non-Hodgkin's lymphoma: an
unusual clinicopathologic association. *Br J Haematol* 2004;124:309–316.
- 36 Lachmann HJ, Gallimore R, Gillmore JD, et al: Outcome in systemic AL amyloidosis in relation
to changes in concentration of circulating free immunoglobulin light chains following chemother-
apy. *Br J Haematol* 2003;122:78–84.
- 37 Kyle R, Gertz M, Greipp P, et al: AL amyloidosis. A trial of three regimes for primary amyloido-
sis: colchicine AL amyloidosisone, melphalan and prednisolone, and melphalan, prednisolone and
colchicine. *N Engl J Med* 1997;336:1202–1207.
- 38 Skinner M, Anderson JJ, Simms R, et al: AL amyloidosis. Treatment of 100 patients with primary
amyloidosis: a randomized trial of melphalan, prednisone, and colchicine versus colchicine AL
amyloidosisone. *Am J Med* 1996;100:290–298.
- 39 Gertz MA, Kyle RA: Acute leukemia and cytogenetic abnormalities complicating melphalan treat-
ment of primary systemic amyloidosis. *Arch Intern Med* 1990;150:629–633.
- 40 Dhodapkar MV, Hussein MA, Rasmussen E, et al: Clinical efficacy of high-dose dexamethasone
with maintenance dexamethasone/alpha interferon in patients with primary systemic amyloidosis:
results of United States Intergroup Trial Southwest Oncology Group (SWOG) S9628. *Blood*
2004;104:3520–3526.
- 41 Palladini G, Perfetti V, Obici L, et al: Association of melphalan and high-dose dexamethasone is
effective and well tolerated in patients with AL (primary) amyloidosis who are ineligible for stem
cell transplantation. *Blood* 2004;103:2936–2938.
- 42 Comenzo RL, Vosburgh E, Falk RH, et al: AL amyloidosis. Dose-intensive melphalan with blood
stem-cell support for the treatment of AL amyloidosis amyloidosis: survival and responses in 25
patients. *Blood* 1998;91:3662–3670.
- 43 Gertz MA, Lacy MQ, Dispenzieri A, et al: Stem cell transplantation for the management of pri-
mary systemic amyloidosis. *Am J Med* 2002;113:549–555.
- 44 Comenzo RL, Gertz MA: Autologous stem cell transplantation for primary systemic amyloidosis.
Blood 2002;99:4276–4282.
- 45 Seldin DC, Anderson JJ, Sanchorawala V, et al: Improvement in quality of life of patients with AL
amyloidosis treated with high-dose melphalan and autologous stem cell transplantation. *Blood*
2004;104:1888–1893.
- 46 Gertz MA, Comenzo R, Falk RH, et al: Definition of organ involvement and treatment response in
immunoglobulin light chain amyloidosis (AL): a consensus opinion from the 10th International
Symposium on Amyloid and Amyloidosis. *Am J Hematol* 2005;79:319–328.
- 47 Skinner M, Sanchorawala V, Seldin DC, et al: High-dose melphalan and autologous stem-cell
transplantation in patients with AL amyloidosis: an 8-year study. *Ann Intern Med* 2004;140:
85–93.
- 48 Lewis WD, Skinner M, Simms RW, Jones LA, Cohen AS, Jenkins RL: Orthotopic liver transplan-
tation for familial amyloidotic polyneuropathy. *Clin Transplant* 1994;8:107–110.
- 49 Pelosi F, Capehart J, Roberts WC: Effectiveness of cardiac transplantation for primary (AL) car-
diac amyloidosis. *Am J Cardiol* 1997;79:532–535.
- 50 Isoniemi H, Kyll Änen L, Ahonen J, Hackerstedt K, Salmela K, Pasternack A: Improved outcome
of renal transplantation in amyloidosis. *Transpl Int* 1994;7:S298–S300.
- 51 Seldin DC, Choufani EB, Dember LM, et al: Tolerability and efficacy of thalidomide for the treat-
ment of patients with light chain-associated (AL) amyloidosis. *Clin Lymphoma* 2003;3:241–246.
- 52 Dispenzieri A, Lacy MQ, Rajkumar SV, et al: Poor tolerance to high doses of thalidomide in
patients with primary systemic amyloidosis. *Amyloid* 2003;10:257–261.
- 53 Palladini G, Perfetti V, Perlini S, et al: The combination of thalidomide and intermediate-dose
dexamethasone is an effective but toxic treatment for patients with primary amyloidosis (AL).
Blood 2005;105:2949–2951.
- 54 Cohen AD, Zhou P, Reich L, et al: Adjuvant dexamethasone (D) ± thalidomide (T) improves
hematologic and organ responses after risk-adapted high-dose melphalan with autologous stem
cell transplant (SCT) for patients with systemic AL amyloidosis (AL). *Blood* 2005;106: 340a.

- 55 Hrcic R, Wall J, Wolfenbarger DA, et al: Antibody-mediated resolution of light chain-associated amyloid deposits. *Am J Pathol* 2000;157:1239–1246.
- 56 O’Nuallain B, Wetzel R: Conformational Abs recognizing a generic amyloid fibril epitope. *Proc Natl Acad Sci USA* 2002;99:1485–1490.

Raymond L. Comenzo, MD, Director
Cytotherapy Laboratory, Memorial Sloan-Kettering Cancer Center
1275 York Avenue
New York, NY 10021 (USA)
Tel. +1 212 639 8086, Fax +1 212 717 3119, E-Mail comenzor@mskcc.org